

Optical coherence tomography monitoring of vocal fold femtosecond laser microsurgery

Henning Wisweh^{a,b}, Ulrich Merkel^a, Ann-Kristin Hüller^a, Kathrin Lürßen^a,
and Holger Lubatschowski^b

^aHannover Medical School, Clinic for Phoniatria and Paediatric Audiology,
Carl-Neuberg-Str. 1, D-30625 Hannover, Germany;

^bLaser Zentrum Hannover e.V., Hollerithallee 8, D-30419 Hannover, Germany

ABSTRACT

Surgery of benign pathological alterations of the vocal folds results in permanent disphonia if the boundaries of the vocal fold layers are disregarded. Precise cutting with a femtosecond laser (fs-laser) combined with simultaneous imaging of the layered structure enables accurate resections with respect to the layer boundaries. Earlier works demonstrated the capability of optical coherence tomography (OCT) for utilization on vocal folds. The layered structure can be imaged with a spatial resolution of $10 - 20\mu m$ up to a depth of $1.5mm$. The performance of fs-laser cutting was analyzed on extracted porcine vocal folds with OCT monitoring. Histopathological sections of the same processed samples could be well correlated with the OCT images. With adequate laser parameters thermal effects induced only negligible damage to the processed tissue. The dimensions of the thermal necrosis were determined to be smaller than $1\mu m$. OCT controlled fs-laser cutting of porcine vocal fold tissue in the μm range with minimal tissue damage is presented.

Keywords: femtosecond laser, ultra short laser pulses, OCT, optical coherence tomography, vocal folds, larynx, microsurgery, phonosurgery, laser tissue ablation

1. INTRODUCTION

The vocal folds of the larynx permit the capacity for phonation. They are composed of different layers that slide against each other. The connective tissue or lamina propria mucosae is located between the epithelium consisting of cellular layers and the vocalis muscle (fig. 1). According to the well-accepted "body-cover-model" introduced by Hirano et al.,¹ these layers perform certain movements as a function of vocal fold tension. The process also relies on a functional separation of muscle ("body") from the lamina propria mucosae ("cover"). This separation has to be respected whenever performing surgery.² Structural changes on vocal folds affect the performance of phonation. Due to the expansion of lesions into deeper layers or tissue loss, the voice becomes unstable and will be limited in frequency and dynamic range. Moreover, scarring of the tissue caused by inadequate wound healing or disregard for the layered structure during surgery can implicate permanent disphonia.

Our aims to precisely treat benign pathological changes with respect to the "body-cover-model" and the prevention of postoperative scarring can not be sufficiently fulfilled by conventional techniques. A suitable tool for very precise tissue ablation is a near-infrared fs-laser. Ultrashort laser pulses focused onto the surface induce a microcut at the focal point by photodisruption. By successively scanning the laser pulses, a three dimensional cut with the accuracy of some micrometers consisting of spots next to each other is created. Due to the fact that photodisruption is a non-linear process nearly all the laser pulse energy is absorbed only within the focal volume. This effectuates the ability to focus the laser beam below the surface and therefore creates microcuts within the tissue without influencing surrounding regions. This technique is well established for transparent media such as the eye.^{4,5} To the best of our knowledge this study is the first to present this application to highly scattering non-transparent vocal fold tissue. As there are no promising techniques known to dissolve scars mechanically inside the vocal folds without affecting surrounding areas fs-laser microsurgery could be a feasible procedure.

Further author information: (Send correspondence to Henning Wisweh)

E-mail: h.wisweh@lzh.de, Telephone: ++49 511 2788 222

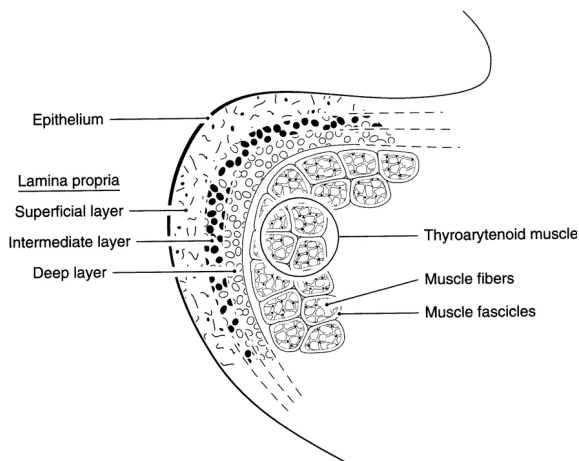


Figure 1. Schematic of a section through the right human vocal fold showing tissue layers.³

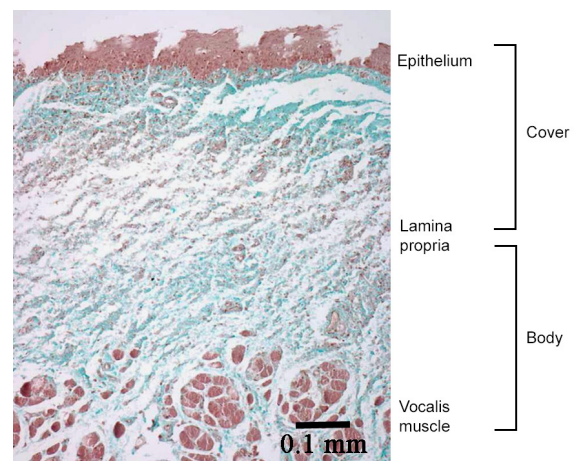


Figure 2. Histological section of a human vocal fold. The thickness of the lamina propria is approximately 1mm.

It becomes evident that an exact intraoperative online diagnosis is necessary for optimizing protection of the epithelium and controlling the subsurface tissue cutting process.

OCT is a novel non-invasive imaging technique⁶ that is already well established in ophthalmology⁷ and dermatology⁸ and is also well suited for application on vocal folds. According to Mahlstedt et al. the depth relevance for its examination correlates well with the penetration depth of the near-infrared light sources generally used for OCT.⁹ The three layers of the lamina propria mucosae differ by their varying densities of collagen and elastin fibers. The so called Reinke space, the superficial layer of the lamina propria mucosae, has a fibrous contingent which is loosely organized. The epithelium of healthy human vocal folds has a thickness of about 0.1mm and the lamina propria mucosae extends to a depth of around 1mm (fig. 2). Thus it is possible to image the layered structure of the vocal folds down to the vocalis muscle.

Several clinical and technical studies at the larynx, particularly at the vocal folds were performed in contact and non-contact mode. Lürßen¹⁰ and Guo¹¹ developed office-based methods that combine indirect laryngoscopy and OCT in order to examine patients without anesthesia. Furthermore, characterization of both benign¹² and cancerous lesions^{13, 14} of human vocal folds during surgery was carried out by different groups. The first and most comprehensive study was done by the Medical Academy and Semashko Clinical Hospital in Nizhny Novgorod, Russia.¹⁵ Klein et al. obtained additional information about the relative collagen content of subepithelial tissue by polarization-sensitive OCT (PS-OCT).¹⁶ However, OCT is used not only used as an additional diagnostic method but also for monitoring interventions such as laser surgery. Tissue ablations with Nd:YAG¹⁷ and CO₂ lasers¹⁸ were obtained and measured with OCT in initial studies. In this study we present OCT-controlled fs-laser ablation of vocal fold tissue on and below the surface.

2. MATERIALS AND METHODS

2.1 Extracted porcine vocal fold tissue

The performance of fs-laser cutting on vocal fold tissue was analyzed ex vivo on extracted porcine vocal folds. The larynges were obtained from a local slaughter house immediately after slaughter and veterinary inspection and were preserved in chilled physiological saline for examination several hours after extraction. Each was cut longitudinally in its median plane. Although the porcine larynx is composed of two folds on each side laser cutting is only performed on the caudal side (fig. 3) following similarities to the human anatomy. For approximation of the in vivo situation the samples were prepared to remain in tension. The layered structure is similar to the human vocal folds but the dimensions differ remarkably. For healthy vocal folds the thickness of the porcine epithelium is in the range of 50 – 75 μ m compared to that of human vocal folds which is 100 – 180 μ m¹⁹ and the lamina propria is also approximately half as thick as the human one.

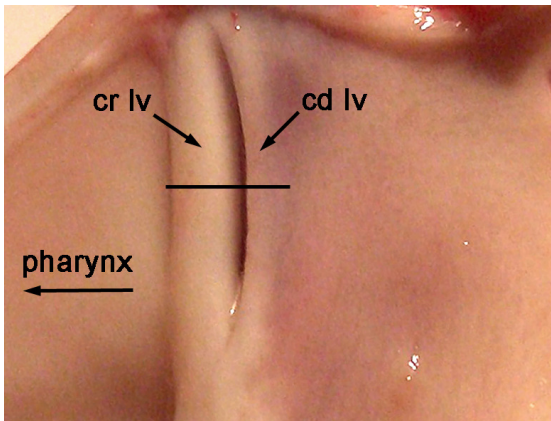


Figure 3. Left half of a porcine larynx. cr lv: cranial ligamentum vocale, cd lv: caudal ligamentum vocale. The black line indicates the section plane for histological preparation.

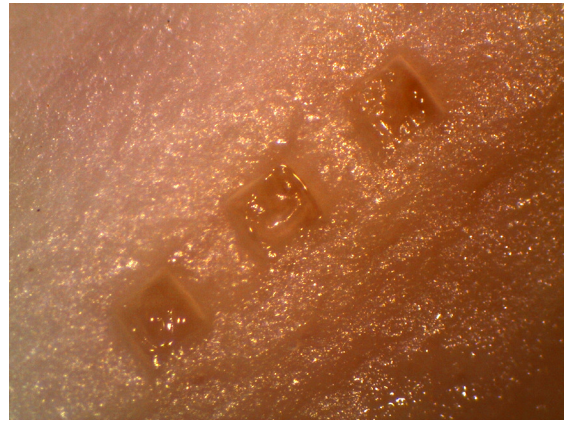


Figure 4. For measurements of ablation rates cubes with different dimensions were ablated. The depicted patterns are $400 \times 400 \times 200 \mu\text{m}$ in size.

After laser treatment and documentation the samples were fixed in 5% formalin for histological preparation. Starting with dehydration in graded ethanol the samples were then embedded in paraffin and cut into $10 \mu\text{m}$ slices before being stained with haematoxylin and eosin or Masson-Goldner. The section planes were transverse to the longitudinal axis of the vocal folds (fig. 3).

2.2 Scanning fs-laser system

The *Thales Bright* system was used for laser treatment of vocal fold tissue. This consists of a Titanium:Sapphire amplifier (center wavelength 780 nm) that is pumped by a frequency-doubled diode-pumped Nd:YAG laser. At a repetition rate of 5 kHz it provides a maximum possible average output power of 1.5 W and therefore a maximum pulse energy of $300 \mu\text{J}$. For estimation of the optical breakdown threshold and measurement of ablation rates the samples were treated with pulse energies in the range of $0.5 - 20 \mu\text{J}$. The pulse duration of 130 fs was determined with a single-shot autocorrelator.

Laser beam scanning in the x-y plane was realized by a galvanometer-scanner unit (*GSI Lumonics*) with a spatial resolution below one micron over a scan field size of 9mm. A mechanical translation-stage with sub-micron resolution was used to perform scanning in the depth by moving the sample relative to the focus. With this three-dimensional user-defined cutting patterns were possible. The beam was focused by an f-theta objective with a focal length of 75mm in order to create a minimum spot size of $5 \mu\text{m}$ and remove distortion over the whole scan field.

2.3 Procedure of OCT-controlled microsurgery

An OCT system developed by *Optimec Ltd.* (Nizhny Novgorod, Russia) was used to position of the samples accurately relative to the focus, thereby avoiding undesired effects due to inaccurate focusing. It offers a spatial resolution of about $15 \mu\text{m}$ at a center wavelength of 1300nm . The fiber optic scanning tip was placed under the galvanometer-scanning unit and a reference located in the focal plane was recorded with OCT. The OCT image could now be used for reference and to control the sample positioning with an accuracy according to the spatial resolution. Because OCT measures optical path lengths the tissue refractive index must be taken into account for determination of the true geometrical tissue dimensions. According to the optical path length measurement technique with OCT introduced by Tearney et al.²⁰ we quantified the refractive index of porcine vocal fold tissue to be $n = 1.39$. This is close to the value for human vocal fold tissue ($n = 1.4$) published elsewhere.¹⁷

After the sample was positioned, the OCT scanner was swiveled out but remains in the adjusted plane. Then fs-laser cutting was performed on the tissue surface or in a selected depth. Therefore ablation of defined volumes as well as planes or lines was possible. After laser treatment the OCT scanner was swiveled in again and the results can be obtained with OCT.

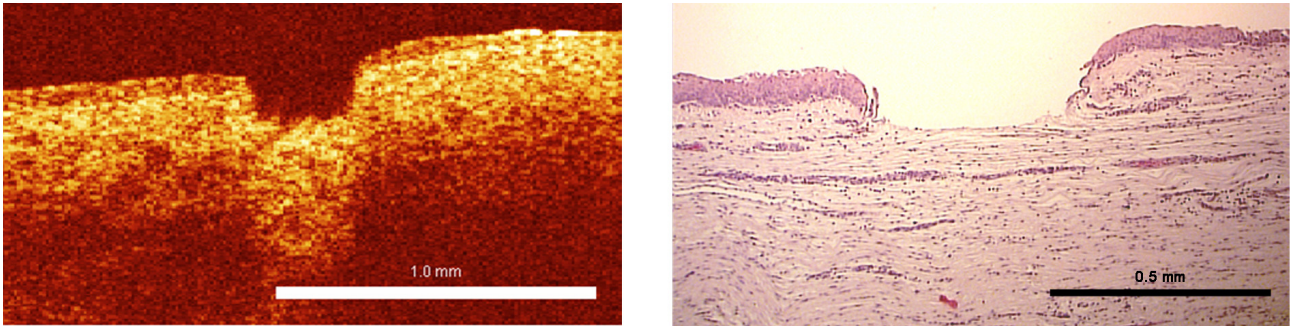


Figure 5. The OCT image of a porcine vocal fold after fs-laser microsurgery (left) can be well correlated with the histological image of the same area (right). The ablated crater has a depth of $185\mu\text{m}$ measured with OCT. The parameters are laser pulse energy: $0.7\mu\text{J}$, number of pulses in z-direction: 100, x-y pulse overlap: 10%, spot size: $5\mu\text{m}$.

2.4 Measurement of ablation results with OCT

Immediately after laser surgery the treated tissue is imaged in situ with OCT in order to quantify the results. For measurements of ablation rates depending on the laser pulse energy, cubes with different dimensions were ablated (fig. 4). These patterns were generated by vertical alignment of x-y planes with definable distances. A pulse overlap of 10% in x- and y-direction was chosen. With the number of pulses equal to the number of x-y planes and the crater depth measured with OCT the ablation rate can be calculated for every applied pulse energy. The refractive index of porcine vocal fold of $n = 1.39$ was taken into account for crater depth determination with OCT. 17 vocal folds of 17 different pigs were treated with an overall number of 35 valuable lesions for ablation measurements.

3. RESULTS

3.1 Superficial tissue ablation

As depicted in figure 5, the OCT images of the ablation results can be well correlated with histological sections of the same treated area. The ablated craters show characteristic structures and therefore the according images could be easily found. The crater depths were measured for all samples with lesions using OCT. The tissue refractive index of $n = 1.39$ was used in order to assure correct geometrical dimensions in OCT images.

Figure 6 shows ablation rates against laser fluence measured with OCT. Laser pulse energies were varied in the range of $0.5 - 20\mu\text{J}$ which corresponds to laser fluences of $2.5 - 10\text{J}/\text{cm}^2$ for a spot diameter of $5\mu\text{m}$. The optical breakdown threshold for vocal fold tissue can be estimated from figure 6. Below an energy of about $0.4\mu\text{J}$ we never obtained a successful ablation. Only thermal damage at the surface due to the incidence of multiple pulses that deposit their energy without inducing photodisruption was observed.

3.2 Subepithelial cutting

It is obvious that positioning the sample relative to the focus has to be performed very precisely in order to achieve cuts with micrometer precision and avoid undesired side-effects. For ablation of benign pathological changes near the surface, the scanning procedure as described in chapter 2.2 must begin on top of the epithelium. If the focus is set within the epithelium, bubbles filled with gaseous ablated tissue arise and damage the epithelium (fig. 7 and 8).

In another approach we set the focus beneath the epithelium to produce cuts without damaging it. Figure 9 and 10 show OCT and histological images of the same porcine vocal fold with a cut in a depth of about $150\mu\text{m}$. It can be seen that for the left part the epithelium is still intact. These results prove the ability of femtosecond lasers to induce microcuts inside of vocal fold tissue and therefore cut through scars.

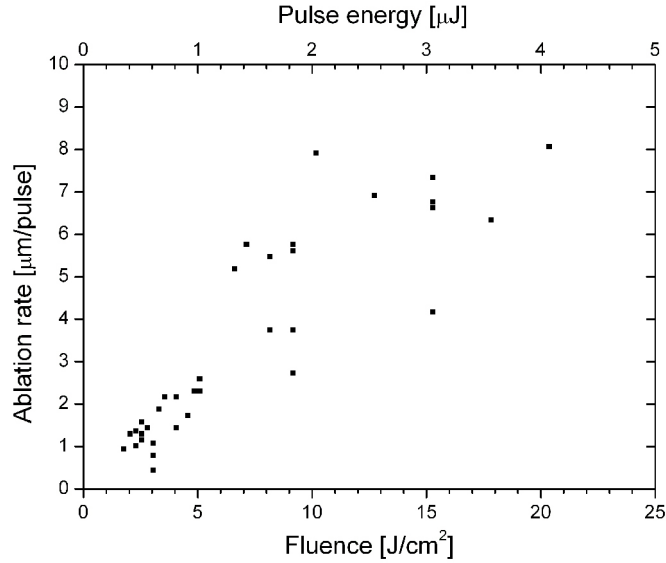


Figure 6. The distribution of ablation rate against laser fluence and pulse energy is almost linear. Applied parameters are spot diameter: $5\mu m$, repetition rate: 5 kHz. The optical breakdown threshold energy can be estimated to approximately $400nJ$.

4. DISCUSSION

Especially at the larynx, where not only the organ itself but also all its functions have to be preserved to the full extent the potential for improvement of operation techniques is huge. Inaccurate tissue ablation can lead to postoperational scarring and at worst to permanent disphonia if the layer boundaries are disrespected during surgery. We have shown that fs-lasers provide the ability to create cuts with micrometer precision without inducing thermal damage. Therefore it is a promising minimally invasive technique for performing tissue-preserving microsurgery on the vocal folds.

Obviously, an intraoperative control is essential if the surgeon uses non-contact methods with no haptic feedback such as laser surgery to maintain the layered tissue structure. In several technical and clinical studies OCT was proven to be an adequate tool for crosssectional vocal fold imaging. As state-of-the-art OCT system designs offer video rate imaging, it is well suited as an online control technique for fs-laser microsurgery.

Femtosecond lasers are also well established in biomedical applications for inducing microcuts inside of transparent tissue such as the eye. In this study we proved that this effect can also be applied to non-transparent highly scattering vocal fold tissue. We achieved cuts with micrometer precision up to a depth of around $150\mu m$ and left the epithelium intact. Therewith we provide the possibility of deviding subepithelial scars. As the cutting patterns can be user-defined in all three dimensions scars that extend in vertical as well as in horizontal direction can be treated. Due to the high intensities in the range of ten Terawatts within the very small focal volume, the effect of non-linear absorption dominates and the penetration depth of the near-infrared light is not limited by linear absorption. Nevertheless, the threshold for an optical breakdown increases with increasing cutting depth due to scattering and absorption outside the focal volume. Therefore higher energies as for superficial ablation have to be chosen which may induce undesired side-effects.

As femtosecond lasers can produce very broad spectra they are appropriate for ultrahigh resolution OCT (UHR-OCT) imaging with axial resolutions in the cellular level.²¹ In combination with the feasibility of cutting biological tissue, a new optical tool for very precise microsurgery with only one light source is conceivable. Amplified pulses could be used for laser therapy and basic oscillator pulses could be used for UHR-OCT to synchronously monitor and guide the treatment.




Figure 7. OCT image of a bubble within the epithelium filled with gaseous ablated tissue taken 30 s after laser treatment.

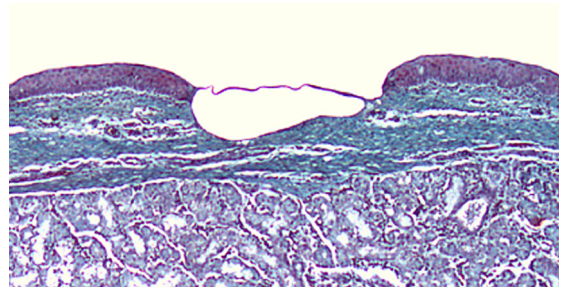


Figure 8. Histological section with Masson-Goldner staining of a bubble within the epithelium.

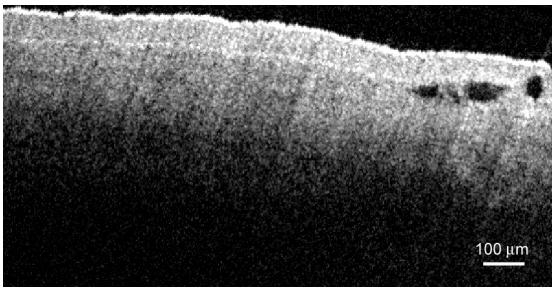


Figure 9. OCT image of a subepithelial cut in a depth of about $150\mu\text{m}$ recorded immediately after treatment. Parameters were spot size: $5\mu\text{m}$, pulse energy: $5\mu\text{J}$.

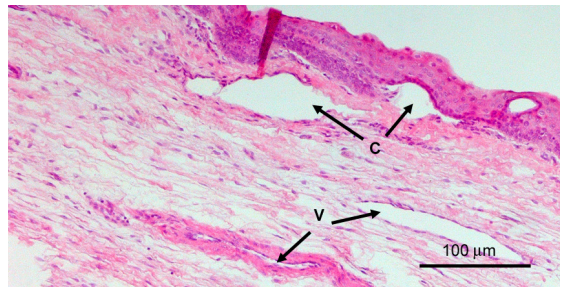


Figure 10. Histological section of the same subepithelial cut. For the left part of the cut the epithelium remains intact. C: laser induced microcut, V: blood vessels.

5. CONCLUSION

With this study we laid the foundation for the development of a combined optical diagnostic and therapy tool for very precise microsurgery of vocal fold tissue. We proved that superficial and subsurface fs-laser ablation with micrometer precision is possible without thermally damaging surrounding areas. Furthermore we judged OCT to be an ideal method for real-time monitoring of vocal fold microsurgery due the adequate imaging depth and its high resolution.

ACKNOWLEDGMENTS

We like to thank Maren Cassens from HIK-Hannover for preparing histological sections and Dr. Marcel Kraft of the University Hospital Giessen and Marburg for good cooperation and exchange of knowledge. We also like to acknowledge the German Ministry of Research and Education (BMBF) for funding (grant 13N8710).

REFERENCES

1. M. Hirano, "Morphological structure of the vocal cord as a vibrator and its variations.," *Folia Phoniatr (Basel)* **26**(2), pp. 89–94, 1974.
2. S. M. Zeitels, "Laser versus cold instruments for microlaryngoscopic surgery.," *Laryngoscope* **106**, pp. 545–552, May 1996.
3. I. R. Titze, *Principles of voice production*, Prentice Hall, 1994.
4. R. M. Kurtz, C. Horvath, H. H. Liu, R. R. Krueger, and T. Juhasz, "Lamellar refractive surgery with scanned intrastromal picosecond and femtosecond laser pulses in animal eyes.," *J Refract Surg* **14**(5), pp. 541–548, 1998.

5. G. Gerten, T. Ripken, P. Breitenfeld, R. R. Krueger, O. Kermani, H. Lubatschowski, and U. Oberheide, "In vitro and in vivo investigations on the treatment of presbyopia using femtosecond lasers," *Ophthalmologie* **104**, pp. 40–46, Jan 2007.
6. D. Huang, E. A. Swanson, C. P. Lin, J. S. Schuman, W. G. Stinson, W. Chang, M. R. Hee, T. Flotte, K. Gregory, and C. A. Puliafito, "Optical coherence tomography.," *Science* **254**, pp. 1178–1181, Nov 1991.
7. W. Drexler, U. Morgner, R. K. Ghanta, F. X. Krtner, J. S. Schuman, and J. G. Fujimoto, "Ultrahigh-resolution ophthalmic optical coherence tomography.," *Nat Med* **7**, pp. 502–507, Apr 2001.
8. T. Gambichler, G. Moussa, M. Sand, D. Sand, P. Altmeyer, and K. Hoffmann, "Applications of optical coherence tomography in dermatology.," *J Dermatol Sci* **40**, pp. 85–94, Nov 2005.
9. K. Mahlstedt, U. Netz, D. Schdel, H. G. Eberle, and M. Gross, "An initial assessment of the optical properties of human laryngeal tissue.," *ORL J Otorhinolaryngol Relat Spec* **63**(6), pp. 372–378, 2001.
10. K. Lueerssen, H. Wisweh, M. Ptok, and H. Lubatschowski, "Optical characterization of vocal folds by oct-based laryngoscopy," *Proceedings of SPIE* **6424**, 2007.
11. S. Guo, R. Hutchison, R. P. Jackson, A. Kohli, T. Sharp, E. Orwin, R. Haskell, Z. Chen, and B. J. F. Wong, "Office-based optical coherence tomographic imaging of human vocal cords.," *J Biomed Opt* **11**(3), p. 30501, 2006.
12. B. J. F. Wong, R. P. Jackson, S. Guo, J. M. Ridgway, U. Mahmood, J. Su, T. Y. Shibuya, R. L. Crumley, M. Gu, W. B. Armstrong, and Z. Chen, "In vivo optical coherence tomography of the human larynx: normative and benign pathology in 82 patients.," *Laryngoscope* **115**, pp. 1904–1911, Nov 2005.
13. W. B. Armstrong, J. M. Ridgway, D. E. Vokes, S. Guo, J. Perez, R. P. Jackson, M. Gu, J. Su, R. L. Crumley, T. Y. Shibuya, U. Mahmood, Z. Chen, and B. J. F. Wong, "Optical coherence tomography of laryngeal cancer.," *Laryngoscope* **116**, pp. 1107–1113, Jul 2006.
14. M. Kraft, K. Lueerssen, H. Lubatschowski, H. Glanz, and C. Arens, "Technique of optical coherence tomography of the larynx during microlaryngoscopy.," *Laryngoscope* **117**, pp. 950–952, May 2007.
15. A. Sergeev, V. Gelikonov, G. Gelikonov, F. Feldchtein, R. Kuranov, N. Gladkova, N. Shakhova, L. Snopova, A. Shakhov, I. Kuznetzova, A. Denisenko, V. Pochinko, Y. Chumakov, and O. Streltzova, "In vivo endoscopic oct imaging of precancer and cancer states of human mucosa," *Optics Express* **1**(13), pp. 432–440, 1997.
16. A. M. Klein, M. C. Pierce, S. M. Zeitels, R. R. Anderson, J. B. Kobler, M. Shishkov, and J. F. de Boer, "Imaging the human vocal folds in vivo with optical coherence tomography: a preliminary experience.," *Ann Otol Rhinol Laryngol* **115**, pp. 277–284, Apr 2006.
17. A. V. Shakhov, A. B. Terentjeva, V. A. Kamensky, L. B. Snopova, V. M. Gelikonov, F. I. Feldchtein, and A. M. Sergeev, "Optical coherence tomography monitoring for laser surgery of laryngeal carcinoma.," *J Surg Oncol* **77**, pp. 253–258, Aug 2001.
18. B. A. Torkian, S. Guo, A. W. Jahng, L.-H. L. Liaw, Z. Chen, and B. J. F. Wong, "Noninvasive measurement of ablation crater size and thermal injury after co2 laser in the vocal cord with optical coherence tomography.," *Otolaryngol Head Neck Surg* **134**, pp. 86–91, Jan 2006.
19. C. Arens, H. Glanz, J. Wnckhaus, K. Hersemeyer, and M. Kraft, "Histologic assessment of epithelial thickness in early laryngeal cancer or precursor lesions and its impact on endoscopic imaging.," *Eur Arch Otorhinolaryngol* **264**, pp. 645–649, Feb 2007.
20. G. J. Tearney, M. E. Brezinski, J. F. Southern, B. E. Bouma, M. R. Hee, and J. G. Fujimoto, "Determination of the refractive index of highly scattering human tissue by optical coherence tomography," *Optics Letters* **20**, pp. 2258–2260, Nov. 1995.
21. W. Drexler, "Ultrahigh-resolution optical coherence tomography.," *J Biomed Opt* **9**(1), pp. 47–74, 2004.